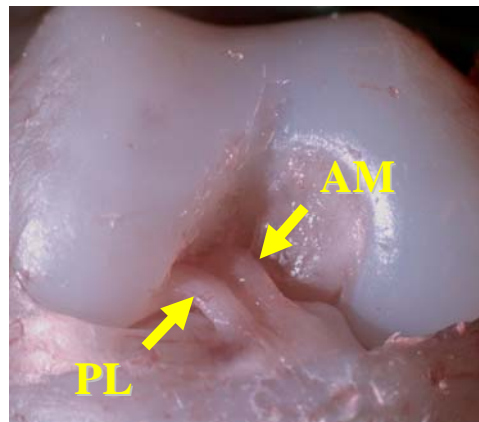


Anatomy of ACL Revisited – Link Between Form and Function

Anatomic Anterior Cruciate Ligament Reconstruction

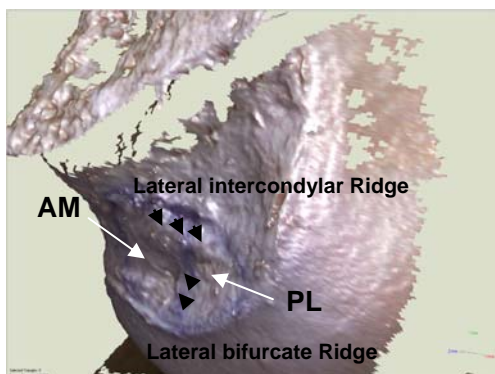
Anterior Cruciate Ligament (ACL) reconstruction is one of the most common procedures performed by orthopaedic surgeons, with approximately 100,000 procedures performed per year in the United States alone. Traditional ACL reconstruction techniques have focused on the reconstruction of the anteromedial (AM) bundle, which is only one portion of ACL. Another portion of the ACL, the posterolateral (PL) bundle, was neglected anatomically and technically. Most recent meta-analysis study (level I) by Biau et al has shown that only 60% of the patients with a traditional one-bundle reconstruction were satisfied with their outcome.

In pursuit of a better understanding of ACL anatomy and function and ultimately better treatment for patients, for the past few years the Department of Orthopaedic Surgery in the University at Pittsburgh School of Medicine has turned its attention on the basic science research of the ACL. Based on our anatomic and biomechanical studies, we have come to an



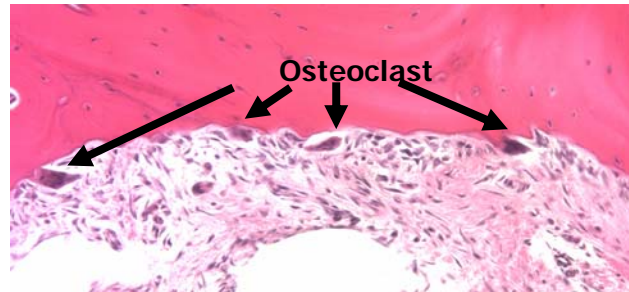
understanding that the two bundles of ACL contribute to the function of ACL differently, with the AM bundle for anterior-posterior stability and the PL bundle for rotational stability. The traditional one-bundle ACL reconstruction does not provide sufficient

rotational stability since it only attempts to reconstruct the AM bundle. It is easy to imagine that if you hang a door by only one hinge the door will hang crookedly, and the bottom may stick and wear unevenly. If you add a second hinge, you make the door more level and eliminate the erosion. The same concept applies to ACL surgery although more clinical trials are




necessary. Furthermore, our anatomy studies have identified bony landmarks of the footprints of native ACL. These bony features are probably formed by responding to the traction forces of ACL and are very useful in locating the anatomic footprints of the AM and PL bundles during arthroscopic ACL surgery.

We have also conducted many biologic, imaging, and kinematic studies of ACL. For example, we have shown that non-anatomic ACL reconstruction can cause advanced bone absorption between graft and



bone tunnels and lead to tunnel widening. By using state-of-the-art in vivo kinematic evaluation (high speed radiography), Dr. Scott Tashman has demonstrated the advantage of anatomic double-bundle ACL reconstruction in restoring intact knee kinematics compared to traditional single-bundle surgery. We believe that the basic science



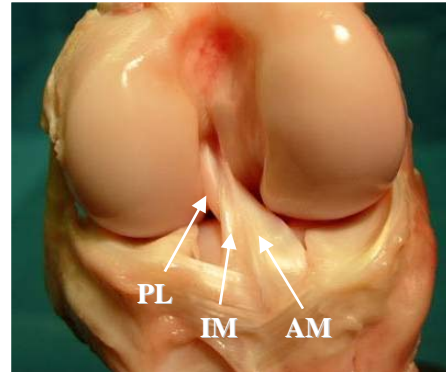
knowledge of the ACL is essential for successful surgical ACL reconstruction techniques and excellent surgical outcome. Our studies have been published in numerous scientific journals and have earned us prestigious awards. In the near future we plan to summarize our research and apply for major financial funding.

In the interim, the Department of Orthopaedic Surgery's Sports Medicine Division has become the world center of anatomic double-bundle ACL reconstruction surgery. Hundreds of surgeons from all over the world have been trained here over the past four years. Most of them have become strong proponents of the double bundle and performed this innovative surgery after returning to their native countries.

Comparative Anatomy of the knee and the ACL

The more we study, the more we want to know. We launched a unique project in collaboration with Carnegie Museum of Natural History, and the Pittsburgh Zoo and PPG Aquarium to study the anatomy of the ACL and its related bony landmarks in different animal species (extinct and extant) as we would like to understand how knee anatomy has evolved according to the knee function of different species.

Freshly frozen specimens of different animals are provided to us by the Pittsburgh Zoo after an animal death from natural causes. The knee anatomy will initially be studied by using CT scan, followed by careful dissection and three-dimensional laser photography to evaluate the gross anatomy of the soft tissues and bony landmarks. We postulate that

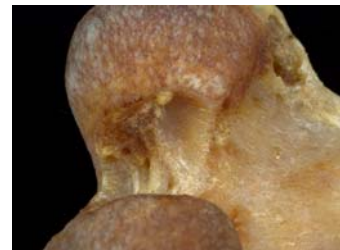

animals in greater need of rotation of the knee will present with a larger ACL, more specifically a prominent PL bundle and a greater difference in the medial and lateral femoral condyles sizes. We will focus our study on primates, a group of more than 300 species including humans, ranging from a palm-size pygmy mouse lemur to a gorilla that can weigh more than 400 lbs.



With the help from Carnegie Museum of Natural History, we will also be able to launch the second part of this study, the bony landmarks of ACL in different species. By using three-dimensional laser

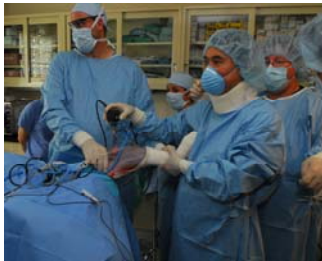photography, the length, area, and angulations of these landmarks will be quantified in these species.



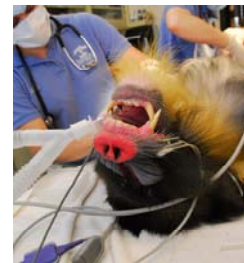

We also have the collaboration of Dr. Owen Lovejoy from Kent State University. Dr. Lovejoy is a world-renowned anthropology professor who was recently elected to the National Academy of Sciences and helped reconstruct “Lucy,” a 3.2 million year-old hominoid discovered in the Afar Triangle of Ethiopia

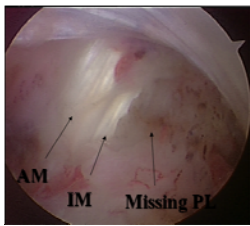
in 1974.



During the initial phase of this project, Johnny, a 12-year-old mandrill monkey (approximately equal to a 25-year-old human being) at the Pittsburgh Zoo started to show signs of knee pain to the veterinarian staff led by Dr. Cindy



Stadler. As a result, Dr. Fu was invited to perform arthroscopic surgery



of the knee for diagnosis and treatment at the Pittsburgh Zoo. Dr Fu and his team found that Johnny had injured his PL bundle and performed a knee debridement. The patient is now in his 7th post-operative month and has not shown any signs of knee pain. This story has been referred in the January 2008 issue of Scientific

American – Body (<http://www.sciam.com/article/id/saving-troubled-knees/SID/mail>). To the best of our knowledge, this is the first time a knee scope has been performed on a monkey.

We hope the knowledge gained from our investigations will help surgeons understand the anatomy and biomechanics of the human knee and, with this, be able to perform a better procedure and allow for a better outcome for their patients. We also hope that we will help shed light on the evolution of the human skeletal system and the origins of human bipedalism.